# Simultaneous PET-MRI reveals brain function in activated and resting state on metabolic hemodynamic and multiple temporal scales

Hans F Wehrl , Mosaddek Hossain, Konrad Lankes, Chih-Chieh Liu, Ilja Bezrukov, Petros Martirosian, Fritz Schick, Gerald Reischl & Bernd J Pichler. Simultaneous PET-MRI reveals brain function in activated and resting state on metabolic, hemodynamic and multiple temporal scales. Nature Medicine

19,1184–1189(2013)

Tuoyu Cao, PET Lab

Advisor: Dr. Paul Vaska

# Why I Think You Should Know About This Work

- The study of brain function is of the utmost interest for basic research and clinical diagnostics
- Simultaneous PET-MRI provides a new way for brain studies

# Background

- Positron emission tomography

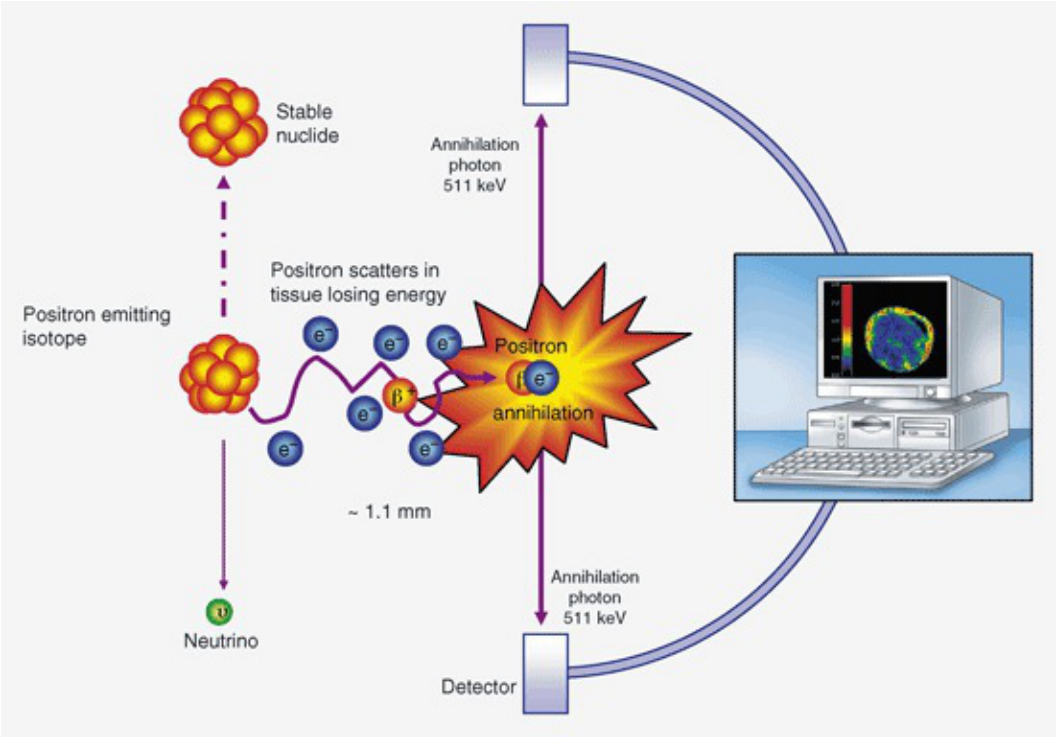


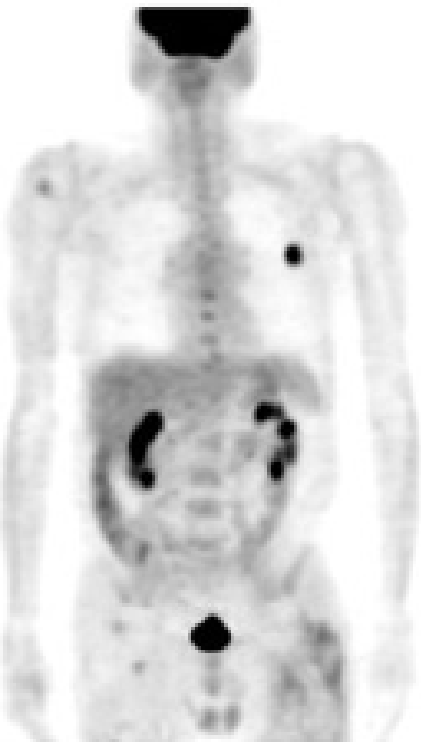

# Background

- BOLD-fMRI

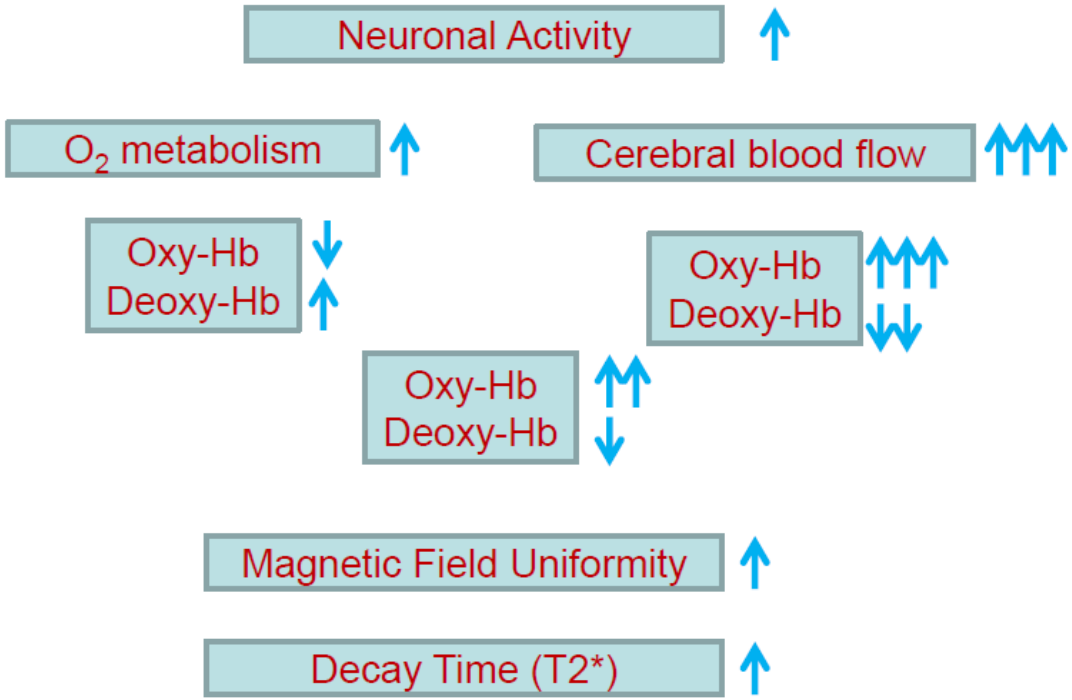


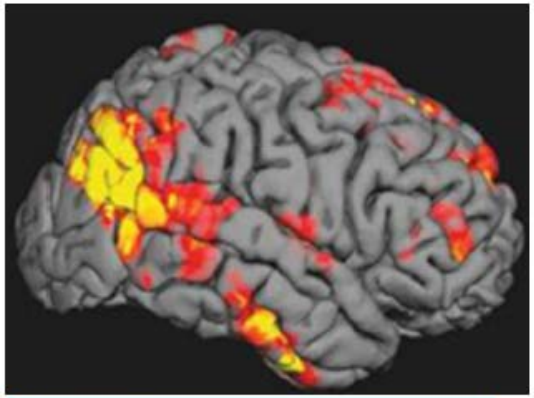

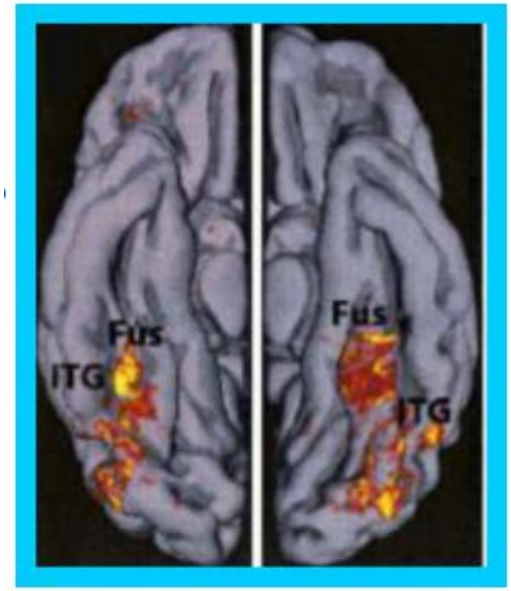

# Background

- PET-MRI
  - More challenges compared to PET-CT
  - Does it provide anything valuable over existing technologies



# Experiment Setup

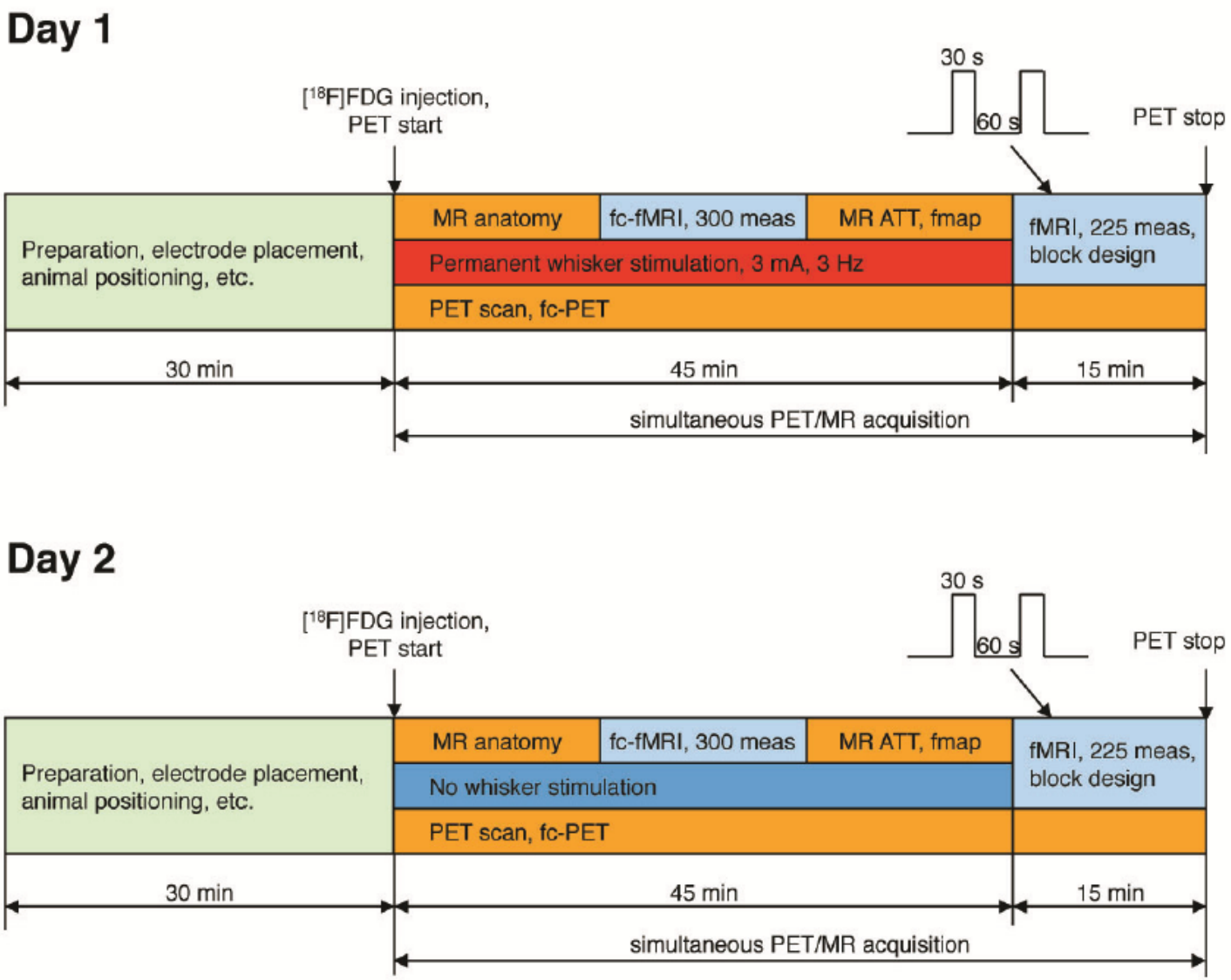

# Results

- Rat studies in the activated state

**Table 1 Activated areas in [$^{18}$F]FDG-PET–BOLD-fMRI**

| Modality | Brain area | Coordinates (mm) | | | *P* value | *T* value |
|---|---|---|---|---|---|---|
| | | *x* | *y* | *z* | | |
| fMRI positive | S1BF cl | 5.9 | −3.2 | −0.7 | $4.4 \times 10^{-16}$ | 22.4 |
| | S1BF il | −6.1 | −3.4 | −0.9 | $3.6 \times 10^{-4}$ | 3.4 |
| | Tha (CPu cl) | 4.9 | −5.9 | −1.7 | $7.7 \times 10^{-6}$ | 4.3 |
| | Tha (CPu il) | −4.9 | −5.9 | 1.7 | $3.3 \times 10^{-2}$ | 1.8 |
| | RSGb, Cg | −0.1 | −4.7 | −3.2 | $6.4 \times 10^{-10}$ | 6.1 |
| | CA1–CA3 | 0.6 | −5.1 | −1.9 | $9.2 \times 10^{-7}$ | 4.8 |
| fMRI negative | S1FL cl | 3.2 | −1.9 | 1.8 | $8.9 \times 10^{-8}$ | 5.2 |
| | S2 il | −7.4 | −5.0 | −1.5 | $2.1 \times 10^{-4}$ | 3.6 |
| PET | S1BF cl | 6.0 | −3.3 | −3.4 | $3.2 \times 10^{-6}$ | 12.0 |
| | Ect, PRh | 6.9 | −7.3 | −2.8 | $1.7 \times 10^{-5}$ | 9.3 |
| | Amyg cl | 5.0 | −9.9 | −3.8 | $3.2 \times 10^{-5}$ | 8.5 |
| | Amyg il | −4.4 | −9.4 | −4.6 | $4.4 \times 10^{-3}$ | 3.6 |
| | Tha (CPu cl) | 4.2 | −6.8 | −2.0 | $6.3 \times 10^{-4}$ | 5.2 |
| | Tha (VPM cl) | 3.0 | −8.0 | −3.7 | $6.7 \times 10^{-4}$ | 5.1 |
| | Tha (VPM il) | −3.0 | −7.0 | −2.8 | $2.0 \times 10^{-2}$ | 4.2 |

# Results

- **Quantification of glucose metabolism and oxygenation changes**

Contralateral S1BF

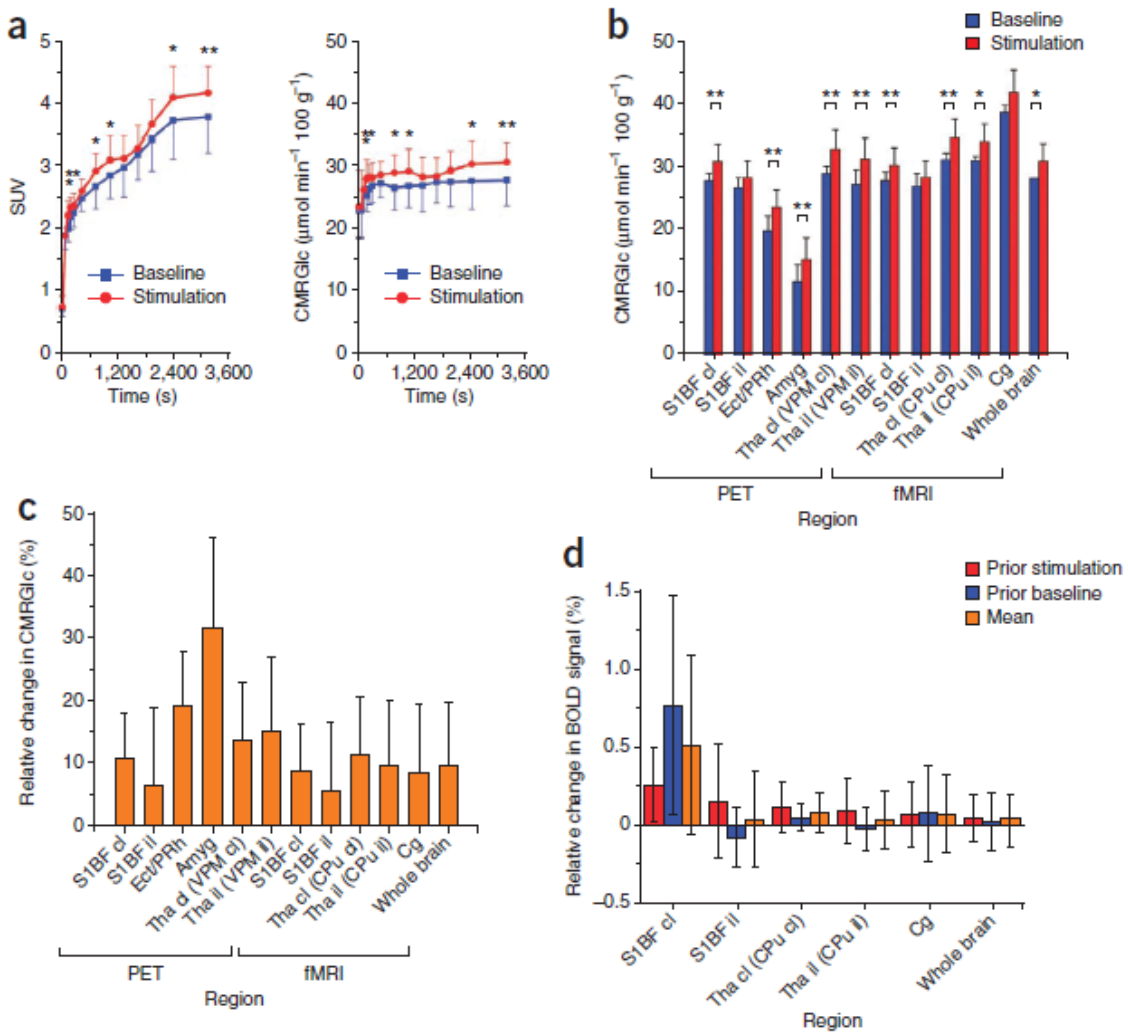

# Functional connectivity and Independent Component Analysis (ICA)

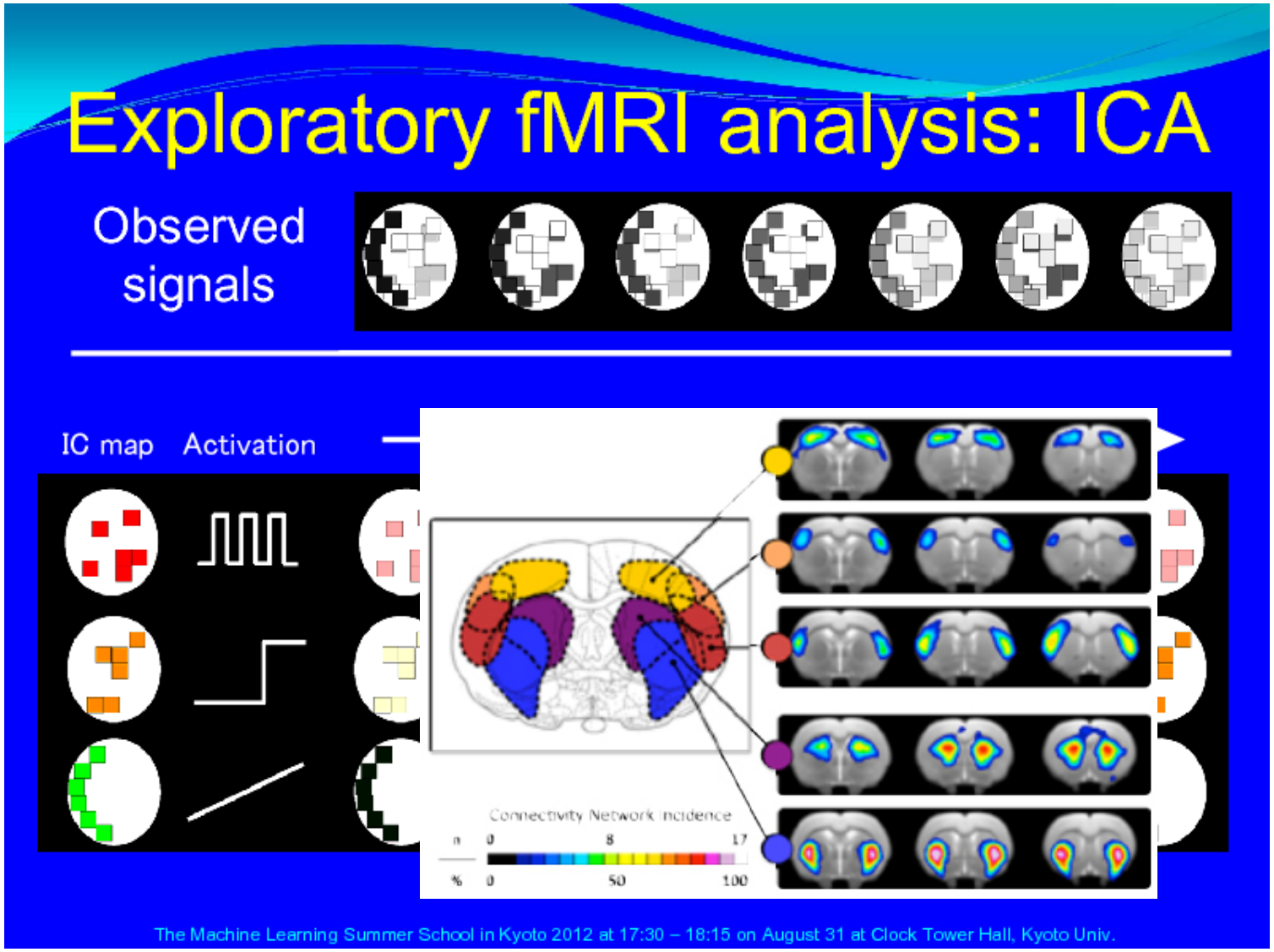

# Results

- **Functional connectivity in stimulated and baseline states**

| Network | fMRI | PET |
|---|---|---|
| Motor Cortex (M1) | C 4, C 8, C 11,<br>3 components linked with S1 | C 13,<br>1 components linked with Striatum / CPu |
| Somatosensory Cortex (S1) | C 4, C 8, C 10,<br>3 components, linked with M1 and CPu | C 7, C 8, C 13,<br>3 components, linked with Dysgranular Cortex |
| Striatum and Tha (CPu) | C 1, C 2,<br>2 components, linked S1 | C 8, C 14,<br>2 components, linked with M1 and Hippocampus |
| Hippocampus | C 13,<br>1 component, linked with Piriform Cortex / Amygdala | C 14,<br>1 component, linked with Striatum / CPu |
| Auditory Cortex | C 5<br>1 component | |
| Cingulate Cortex | C 7<br>1 component | C 14<br>1 component |
| Dysgranular Cortex | C 7<br>1 component | C 4<br>1 component |
| Entorhinal Cortex | C 10<br>1 component | |
| Piriform Cortex/ Amygdala | C12, C13,<br>2 components, linked with Hippocampus | C5, C8,<br>2 components, linked with Striatum / CPu |

# Results

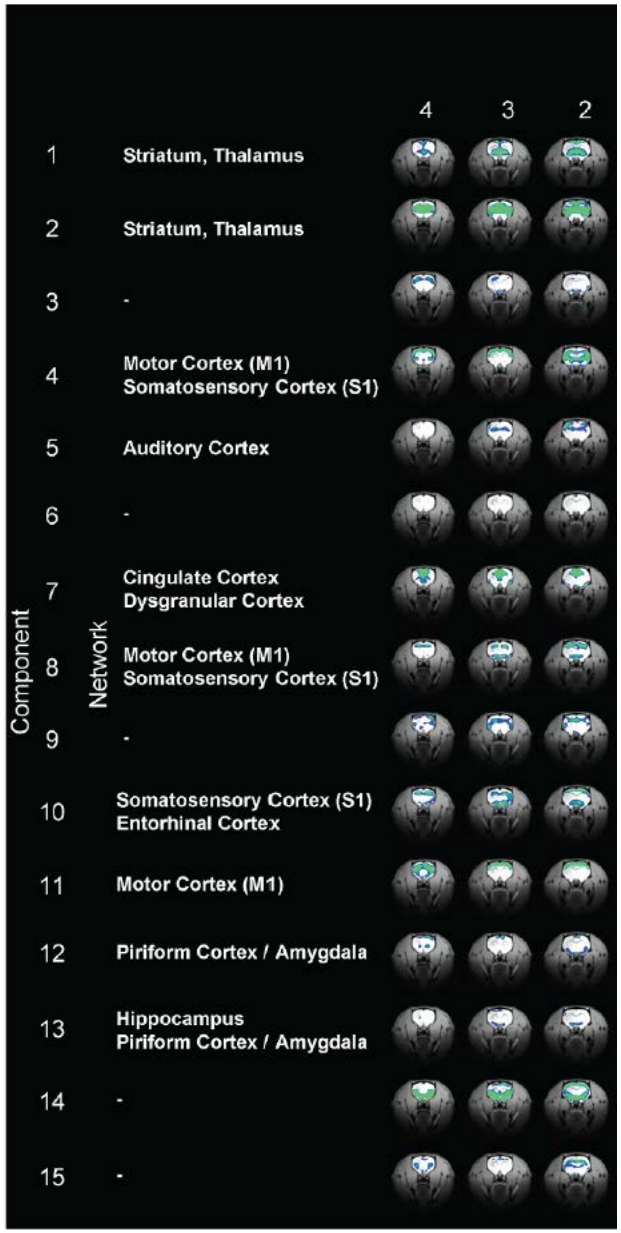
4 3 2
Component
Network
1 Striatum, Thalamus
2 Striatum, Thalamus
3 -
4 Motor Cortex (M1)
Somatosensory Cortex (S1)
5 Auditory Cortex
6 -
7 Cingulate Cortex
Dysgranular Cortex
8 Motor Cortex (M1)
Somatosensory Cortex (S1)
9 -
10 Somatosensory Cortex (S1)
Entorhinal Cortex
11 Motor Cortex (M1)
12 Piriform Cortex / Amygdala
13 Hippocampus
Piriform Cortex / Amygdala
14 -
15 -

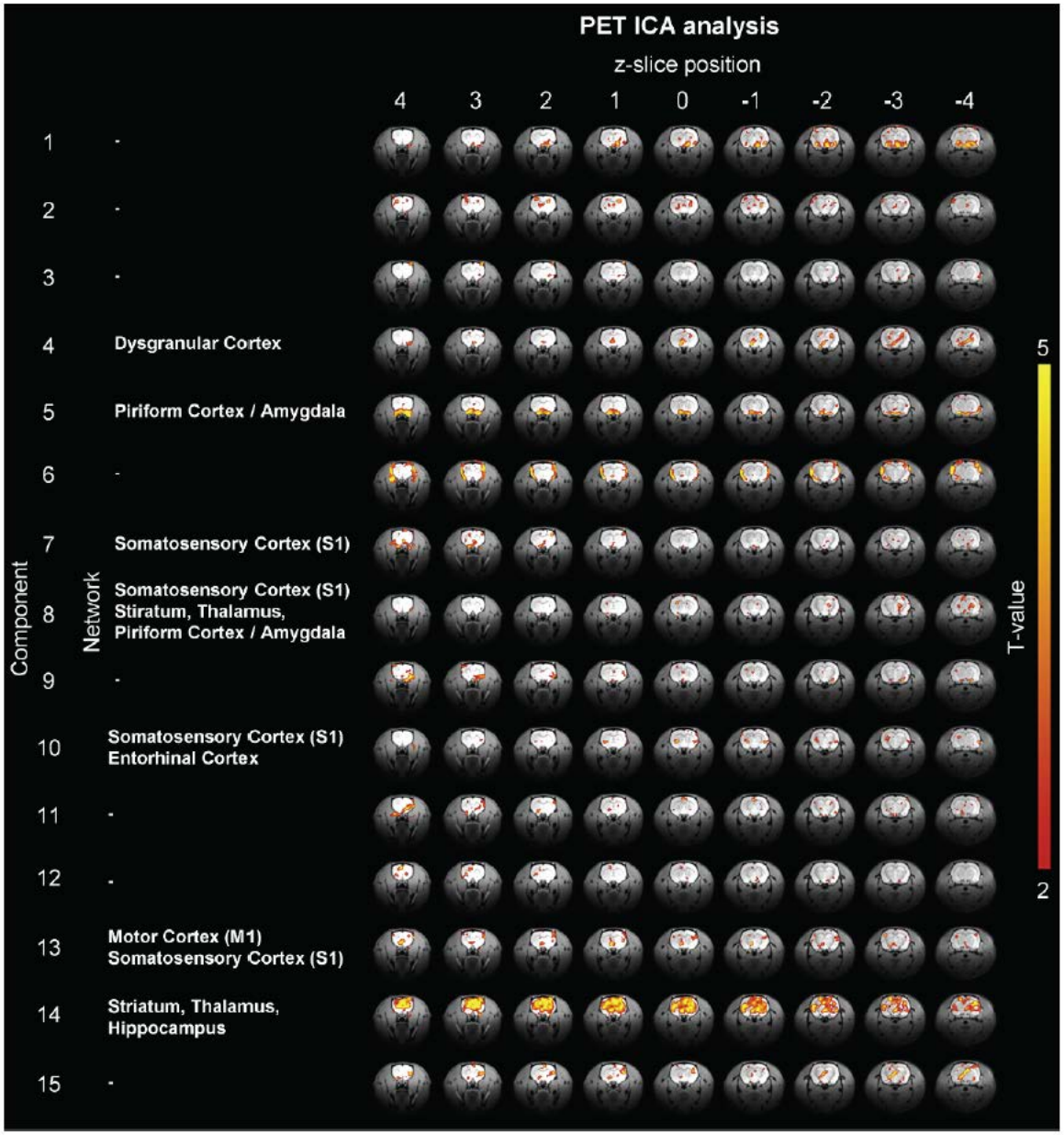
PET ICA analysis
z-slice position
4 3 2 1 0 -1 -2 -3 -4
Component
Network
1 -
2 -
3 -
4 Dysgranular Cortex
5 Piriform Cortex / Amygdala
6 -
7 Somatosensory Cortex (S1)
8 Somatosensory Cortex (S1)
Striatum, Thalamus,
Piriform Cortex / Amygdala
9 -
10 Somatosensory Cortex (S1)
Entorhinal Cortex
11 -
12 -
13 Motor Cortex (M1)
Somatosensory Cortex (S1)
14 Striatum, Thalamus,
Hippocampus
15 -
5
T-value
2

# Conclusions

- Feasibility of simultaneous PET and fMRI
- PET-fMRI shows comprehensive and complementary information
- Further potential of using different PET tracers and MRI protocol