Brain Region Morphological and Volume Quantitative Assessment using the 17.6 T MRI in Rats Chronically Exposed to Methylphenidate

Vasilios Boronikolas[1], Michael Michaelides[1], Gene-Jack Wang[1], Steve Blackband[2], Samuel C. Grant[2], Nora D. Volkow[3] and Panayotis K. Thanos[1,3]

[1]Behavioral Neuropharmacology and Neuroimaging Lab, Medical Department Brookhaven National Laboratory, Upton, NY 11973; [2]University of Florida McKnight Brain Institute, Department of Neuroscience Gainesville, FL 32610-0244; [3]NIAAA Intramural Program, NIH, Bethesda, MD 20892 **thanos@bnl.gov ; http://www.bnl.gov/thanoslab**

Objectives

Methylphenidate (MP) remains the primary pharmacotherapy for treatment of ADHD. It has not been determined though what impact long-term treatment with this psychostimulant would have on behavior, neurochemistry or neuroanatomy. Previous results have shown that long term-exposure to MP in adolescent rats have produced changes in dopamine D2 receptor levels and significantly enhanced cocaine self-administration in adulthood (Thanos et al. 2004; 2006). Here we measured the effects of chronic treatment (8 months) with oral MP (1 or 2 mg/kg) or water, which was initiated in adolescent rats (4 weeks old). Following this treatment, rats in adulthood (9 mo old) were perfused intracardially and their brains removed and imaged with a 17.6 T MRI for neuroanatomical volume assessment.

Methods

We used 750 MHz Spectrometer (Wide Bore) for each of the 9 brains imaged, and we implement an in vitro magnetic resonance imaging of the 3 groups of rats. Each rat brain scan generated two different types of images: one 3D gradient echo (GE) image acquired at high resolution (50x50x50-micron isotropic resolution) and one diffusion-weighted multislice spin echo (2DDWSE) acquired at a lower resolution (62x64.4x250-micron resolution), particularly in the 3rd dimension. The images of all the rats in each group were segmented using the AMIRA software in the following regions of the rat brain: Cerebellum, Caudate putamen, Hippocampus, External Capsule, Neocortex and Fimbria of Hippocampus. After the segmentation of the images we will calculate volumes of the specific rat brain regions.

Results & Conclusion

Images will be analyzed qualitatively and quantitatively in terms of volume of the different brain regions across treatment group. A representative example of a horizontal plane of the rat brain with regions of interested outlined is included in Figure 1. This analysis will allow us to determine using the 17.6 T MRI; the impact of chronic oral MP treatment in rats on brain morphology without freezing and sectioning the brain. In addition, these results will allow us to study 3 dimensionally the different brain regions without the error traditionally found in stereological neuoranatomical studies. Furthermore these results will be compared with behavioral and neurochemical findings as well as in vivo MRI assessment performed longitudinally in similar treated animals.

Research Support. This research has been funded by a Laboratory-Directed Research and Development (LDRD) grant from Brookhaven National Laboratory, provided by the U.S. Department of Energy and the NIH NIAAA intramural research program.
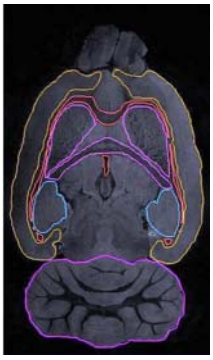
Figure 1.